

Gustavo Cabello
 María Rioboo
 Javier G. Fábrega

Immediate placement and restoration of implants in the aesthetic zone with a trimodal approach: soft tissue alterations and its relation to gingival biotype

Authors' affiliations:

Gustavo Cabello, Private Practice, Málaga, Spain
 María Rioboo, Private Practice, Madrid, Spain
 Javier G. Fábrega, Private Practice, Madrid, Spain

Corresponding author:

Gustavo Cabello
 Clínica NEXUS
 Calle Méndez Núñez, 12; 1
 Málaga 29008, Spain
 Tel.: +34 62 569 3980
 Fax: +34 95 206 0758
 e-mail: info@clinicalexus.com

Key words: aesthetics, dental implants, flapless, gingival biotype, gingival recession, immediate implants, immediate loading, immediate provisional restoration, papilla, single tooth replacement, trimodal approach

Abstract

Purpose: The aim of this prospective study was to evaluate the soft tissue changes around implants in the aesthetic zone, placed under a trimodal approach (immediate post-extraction placement, flapless, and immediate provisional restoration) and its relationship to gingival/periodontal biotype of the patient.

Materials and methods: The sample consisted of 14 patients from two private practices that were in need of a tooth extraction in the anterior maxillary region (cuspid to cuspid) and were candidates to a replacement with a dental implant. An initial measurement (baseline) of the position or the mesial and distal papillae and gingival zenith was made at this time, with a rigid dental-supported stent and an electronic precision caliper, able to the second tenth of a millimeter; after careful tooth extraction, the periodontal thickness, at a point 5 mm apical to de gingival buccal margin, with an analogical thickness gauge, able to one tenth of a millimeter. Once the implant was inserted an immediate provisional restoration was delivered. To evaluate the soft tissue changes measurements were repeated at 3, 6, and 12 months. A statistical analysis was performed to evaluate the changes in the gingival margin around the implant restorations and to identify a possible correlation to patient's periodontal thickness.

Results: All 14 patients received Straumann® implants (9 Tissue Level [TL] Regular Neck [RN], 2 TL Narrow Neck [NN], 2 Bone Level [BL] Narrow Crossfit [NC], and 1 BL Regular Crossfit [RC]). All implants integrated and none had any biological complications. Three provisional restorations presented screw loosening and retightened once and one loss retention and was recemented once. In one patient, with a severe bruxing habit, the final restoration suffered screw loosening and was retightened. Of the final restorations, 12 were screw-retained and 2 cemented on custom-made Zirconia abutments. A mean recession of the buccal margin of 0.45 mm was recorded at 12 months (± 0.25 mm). An acceptable papilla level was present in all cases at 1 year, with mean changes of 0.38 mm (± 0.60) for the mesial and 0.80 mm (± 0.90) of the distal papilla, respectively. No correlation could be established between the soft tissue changes and the periodontal biotype of the patient.

Conclusions: Within the limitations of this study, the good aesthetic outcome and minimal complications seem to validate the trimodal approach protocol as a reliable and simple protocol to place and restore immediate implants in the aesthetic zone. No correlation between the patient's gingival biotype and the soft tissue alterations could be established. Additional studies are needed to verify long-term aesthetic results with this approach and to better define and quantify biotypes.

Date:

Accepted 10 May 2012

To cite this article:

Cabello G, Rioboo M, Fábrega JG. Immediate placement and restoration of implants in the esthetic zone with a trimodal approach: soft tissue alterations and its relation to gingival biotype.
Clin. Oral Impl. Res., 2012, 1–7
 doi: 10.1111/j.1600-0501.2012.02516.x

Following tooth extraction a biological cascade of events take place in the healing process of the alveolar bone, which may considerably affect the external architecture of the gingival tissue (Chen et al. 2004). The predictability of immediately post-extraction placed implants

has been shown to be very similar, when compared to that of implants placed in healed bone (Bianchi & Sanfilippo 2004; Norton 2004; Lang et al. 2007; Quirynen et al. 2007).

Recent clinical and pre-clinical studies concluded that immediate implant placement

will not affect the physiologic remodeling in the post-extraction socket (Schropp et al. 2003; Cardaropoli et al. 2007; Araújo et al. 2005, 2006a, b; Vignoletti et al. 2009), as this process is associated to the resorption of the bundle bone that follows tooth extraction. This may be significant when the very shallow buccal wall is considered, quite often comprised exclusively of bundle bone.

Other studies suggest that tooth extractions (Fickl et al. 2008a) or immediate implant placement using a flapless approach will result in a reduced alteration of the soft tissue contour (Blanco et al. 2008), as this technique would minimize surgical trauma and, consequently, osteoclastic activity in the area.

Immediate implant placement in the anterior maxilla seems an attractive option, as it is possible to control implant position in single rooted sockets and it minimizes the total treatment time from extraction to final restoration. However, numerous articles warn about the risk of unpredictable tissue healing when immediate implants, with or without an immediate provisional restoration, are implemented, showing mean retraction of the soft tissues of 0.5–1 mm (Groisman et al. 2003; Kan et al. 2003, 2011; Gotfredsen 2004; Evans & Chen 2008).

A number of factors have been analyzed concerning the final contour of the buccal soft and hard tissue when immediate implants are implemented. Some of these are dimensions of the periodontum and implant position (Chen et al. 2007; Evans & Chen 2008), flap vs., flapless approach (Blanco et al. 2008; Fickl et al. 2008a), distance from the implant neck to the buccal bone wall (Paolantonio et al. 2001; Botticelli et al. 2003b), filling or not this space with any bone substitutes (Iasella et al. 2003; Chen et al. 2007; Juodzbalys & Wang 2007; Araújo et al. 2009) and the placement of immediate implant-supported provisional (Chaushu et al. 2001; Groisman et al. 2003; Kan et al. 2003; Atieh et al. 2009). Although no single factor seems to be determinant in the final aesthetic outcome, most authors agree on the must of an intact buccal bone wall and ideal implant position, when immediate implants are selected as the treatment option.

In selected patients, an immediate implant-supported provisional restoration may be delivered at time of surgery (bimodal approach) (Atieh et al. 2009). When a flapless approach is added to the procedure (Schwartz-Arad & Chaushu, 1998) the risk increases as no visual references of the shape and volume of the buccal bone wall is available. In spite of all these considerations, this protocol is

often selected as the best treatment option, as it reduces trauma and treatment time, provides immediate aesthetics and comfort, altogether making it very well accepted by the patient (Kan et al. 2003). This procedure could be named as “trimodal approach”, for it includes immediate post-extraction implant and provisional restoration placement with a flapless protocol.

The aim of this study was twofold: first, to analyze the changes of the vestibular mucosal margin and mesial and distal papillae, after tooth extraction, immediate implant placement and immediate provisional implant-supported restoration delivery, in a flapless mode (Trimodal Approach) in the aesthetic zone. Second, to identify any correlation of these changes to the patient's periodontal dimensions (gingival biotype).

Materials and methods

A series of 14 patients from two private practices (GC and JGF), in need of single implant-supported restorations in the anterior maxilla (incisors or cuspids) were selected for this study, under the following exclusion criteria:

- Systemic metabolic or osseous disease that could compromise peri-implant tissue healing.
- Patients under 20 years of age.
- Acute infection in the treatment area.
- Absence of one or both adjacent teeth.
- History of periodontal disease with probing over 3 mm.
- Osseous defects in the buccal bone wall (dehiscence or fenestration) observed during surgery, or when the tooth extraction altered the integrity of the osseous and gingival architecture.

Treatment sequence

First visit

- Patient's data collection. Signed informed consent. Study casts. Preoperative photographs (with lip retractors, including 13–23).
- Periapical radiograph of problem tooth, using X-ray ring to obtain parallel technique.

Lab work

On the study cast, a rigid stent is prepared with light-cured resin, covering the incisal edges of at least, one adjacent tooth in each side of the target tooth, (see Fig. 1) The stent is > 2 mm thick so it can be modified to allow seating over the final restoration.

Second visit

a Pre-op records:

- Distance from stent to distal papilla (DP), mesial papilla (MP), and gingival zenith (Z). Distances are measured by means of a precision digital caliper that can display down to tenths of a millimeter. Three dimples are ditched in the stent, approximately in the vertical projection of papillae and zenith (see Figs 1–3).
- Sulcus probing. Six point: buccal (M, D, and MB) and lingual (M, D, and ML).
- Probing to bone (M, D, and MB).

b Surgical procedure:

- Careful tooth extraction, avoiding trauma to the osseous crest (in seven patients the Benex Extractor[®] (Benex Root Extraction System, Hager and Meisinger GmbH, Neuss, Germany) was used, to ensure atraumatic extraction). Following tooth extraction, a careful examination of the buccal bone wall was performed to verify its integrity. If this was not the fact, the patient was excluded from the study and the implant was placed by means of conventional protocols, including most of the times flap elevation and simultaneous guide bone regeneration.

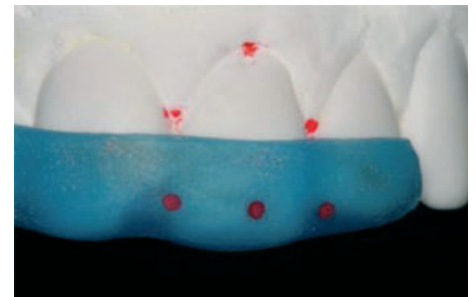


Fig. 1. Rigid photo-cured acrylic stent made on study model. Note three fixed reference points to measure soft tissue changes around implant restoration.

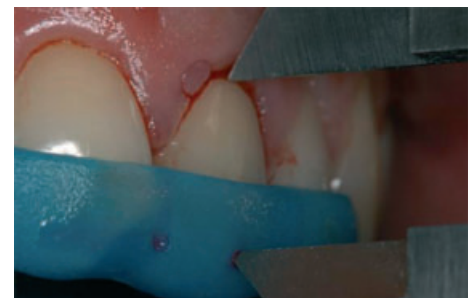

Fig. 2. Measurement with electronic caliper with rigid stent before tooth extraction.

- Measurement of the total periodontal thickness by means of an analogic caliper able to show tenths of a millimeter, at a point 5 mm apical to the buccal gingival margin (Figs 4 and 5).
- All implants were placed with a flapless approach. Ideal position was attempted, at 2 mm of depth for the TL implant and 3 mm for the BL implant and 2 mm palatal to de buccal bone wall for all implants. It was also verified that the wall of the post-extraction socket was not perforated during implant bed preparation. Implant had to show good primary stability in its ideal position. No material was used to fill the gap between the implant and



Fig. 3. Digital screen of the electronic caliper showing actual measurement to second tenth of a millimeter.

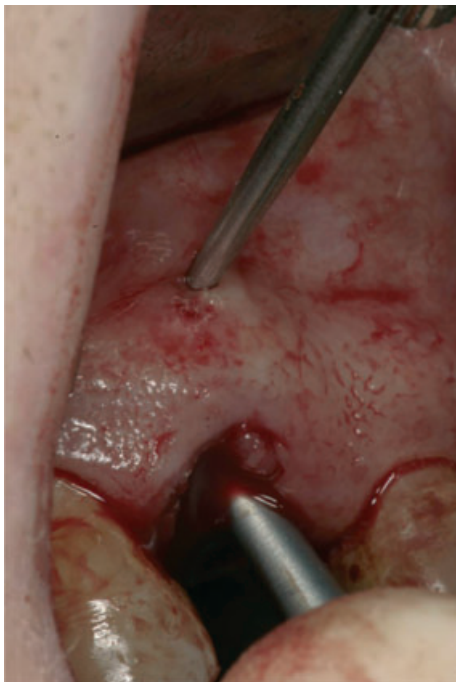

Fig. 4. Measurement of total thickness of the periodontium (biotype) with an analogical gauge, at a point 5 mm from buccal gingival margin.

the osseous wall and no soft tissue graft was attempted either.

- Following implant placement, acrylic resin implant-supported provisional restoration was prepared, adapted and delivered. All provisional restorations were either cemented on a customized abutment or screw-retained and designed with no occlusal contacts, neither in maximum intercuspation nor in excursive movements. Emergence profile was mainly flat or concave in interproximal and palatal sides, and slightly convex in the buccal aspect to support the soft tissues.
- An intra-oral radiograph was made to check implant position and restoration seating.
- Systemic antibiotics (Amoxicillin 500–750 mg/8h/7day) and anti-inflammatories (Ibuprofen 600 mg/8h/3day) were prescribed, together with a chlorhexidin mouth rinse twice a day for 10 days
- Patient was then observed after 2 weeks for a post-operative control.

Final restorative phase

At 3 months, final impression was made. After abutment selection and bisque try-ins, final restorations were permanently placed at 4 months. 10 of the crowns were metal-ceramic, directly screw-retained, two were Zirconia-based crowns cemented on a prefabricated Zr abutment (Straumann Anatomical IPS e.max Abutment [Institut Straumann AG, Basel, Switzerland]) and two were a Zr abutment anatomically developed with aesthetic ceramic and directly screw-retained. Different steps of the clinical protocol are illustrated in Figs 6–10.

Follow-up

Patient examinations and measurements were performed by each investigator in his office at 2, 4, and 6 weeks, 3, 4, 6, and 12 months, and the following points were recorded:

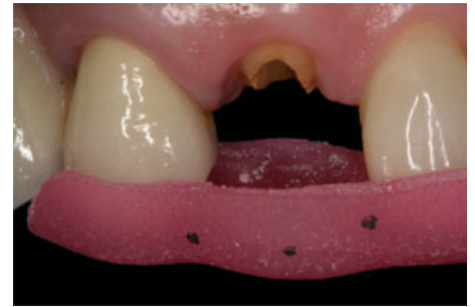

Fig. 6. Preoperative labial view of a failing maxillary right cuspid with the rigid stent.

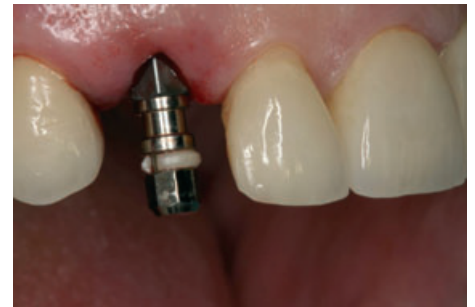

Fig. 7. TE Straumann® implant after insertion in ideal position for direct screw retention of provisional restoration.

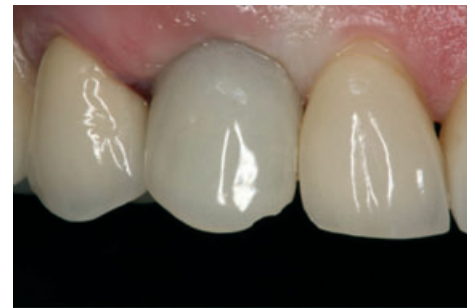

Fig. 8. Immediate provisional restoration after flapless procedure (trimodal approach).

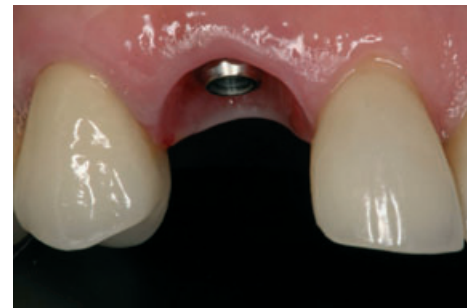

Fig. 9. Clinical view of peri-implant tissues prior to final restoration delivery.

- Any biological (bleeding, probing > 5 mm, suppuration or implant mobility) or mechanical (screw loosening, loss of retention, chipping of acrylic or porcelain) complication.



Fig. 5. Detailed view of measurement of periodontium with the caliper.

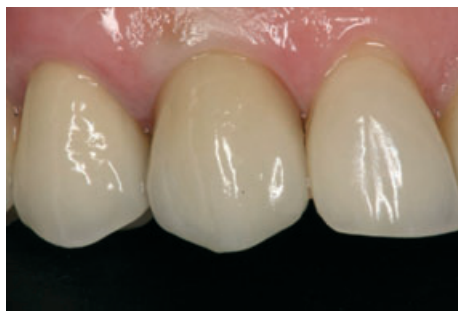

Fig. 10. Final restoration in place (metal-ceramic, direct screw-retained).

- Distance from reference measuring points on the stent to mesial (MP) and distal (DP), papillae and gingival zenith (Z) of the implant restoration.

Statistical analysis

Data analysis was performed using the patient as the experimental unit. For all parameters

mean values and SD per subject and per visit as well as the proportions were calculated. Intra-group comparisons, between baseline and the different moments of the study monitoring were assessed by the paired *t*-test.

Association among dimensional changes between different moments and baseline and the width and thickness of the periodontium was analyzed with Pearson correlation.

Results

A total of 14 patients were included in the study and presented a mean age of 52 years (34–71), seven were men and seven women. Thirty-six percent were smokers. Other descriptive data are presented in Table 1. One of the patients (NI) was a heavy bruxer.

All 14 implants showed uneventful healing and integrated (survival rate 100%). None of them presented biological complications. Three provisional restorations had screw

loosening (retightened at recommended torque once) and a cemented one loss retention (recemented once) in the first 3 months. One final restoration presented loosening at 6 months, interestingly in the patient with the bruxing habit.

The changes in the peri-implant soft tissue levels are presented in Table 2. The mean recession at the zenith was 0.45 mm (SD ± 0.25). Changes in papilla height showed an increased variability as they were probably more influenced by the contour of the final restoration, but were acceptable according to the papilla index (Jemt 1997).

No statistically significant correlation could be established between the thickness of the periodontal tissue (gingival biotype) as measured with caliper or the width of the queratinized mucosa, with the alterations that occurred from the time of the procedure and over the 12 months of the observation period (Table 3).

Discussion

Immediate implants have become a routine procedure as they have a similar survival rates when compared to implants placed in healed bone. Immediate (type 1) protocol is readily accepted by clinicians and patients, as it implies one single surgical intervention, less trauma, may provide immediate aesthetics and comfort and it shortens total treatment time (Bianchi & Sanfilippo 2004; Norton 2004; Lang et al. 2007; Quirynen et al. 2007). However, this protocol is considered aesthetically risky by many, as post-extraction healing of the alveolar bone may lead to unpredictable changes of the peri-implant tissues thus altering the gingival architecture and contour. It has been proven that bone remodeling always takes place, even when an immediate implant is placed, as this phenomenon is associated to the resorption of the bundle bone, present only around the natural teeth (Araújo et al. 2005, 2006a, b). This process seems to particularly affect the integrity of the often thin buccal

Table 1. Patients and implants description (n = 14)

Variable	n (%)	Mean ± SD	Median
Patients baseline clinical characteristics			
Age (range 34–71)		52.3 ± 13.4	58.0
Gender			
Females	7 (50.0)		
Males	7 (50.0)		
Tobacco			
Non smokers	9 (64.3)		
Smokers	5 (35.7)		
Baseline characteristics at implant placement			
Implant			
BL	3 (21.4)		
NN	2 (14.3)		
RN	9 (64.3)		
Reason for tooth extraction			
Caries/Endodontic	3 (21.4)		
Fracture/No ferrule	10 (71.4)		
Internal resorption	1 (7.2)		
Probing depth (mm)			
Mesial		2.64 ± 0.63	3.00
Facial		2.64 ± 0.93	2.00
Distal		2.57 ± 0.65	2.50
Probing bone level (mm)			
Mesial		4.50 ± 0.65	4.00
Facial		4.21 ± 1.05	4.00
Distal		4.14 ± 0.86	4.00
Gingival width (mm)		7.14 ± 1.51	6.50
Gingival thickness (mm)		1.65 ± 0.52	1.58

Table 2. Dimensional mesial, facial, and distal gingival level changes between different follow-ups and baseline

Follow-up	n	Mesial			Facial			Distal		
		Mean ± SD	Median	P-value*	Mean ± SD	Median	P-value	Mean ± SD	Median	P-value
Provisional	14	0.06 ± 0.49	0.05	0.463	0.16 ± 0.40	0.06	0.235	0.19 ± 0.54	0.14	0.196
1 month	10	0.45 ± 0.41	0.33	0.005	0.39 ± 0.52	0.37	0.037	0.87 ± 0.88	0.77	0.017
12 weeks	10	0.60 ± 0.44	0.68	0.008	0.43 ± 0.40	0.34	0.012	0.75 ± 0.92	0.60	0.028
16 weeks	5	0.86 ± 0.62	1.17	0.080	0.45 ± 0.40	0.36	0.080	1.31 ± 0.53	0.84	0.080
6 months	12	0.49 ± 0.68	0.32	0.091	0.31 ± 0.67	0.43	0.034	0.86 ± 0.96	0.81	0.008
12 months	13	0.38 ± 0.60	0.41	0.050	0.45 ± 0.25	0.39	0.002	0.80 ± 0.96	0.74	0.016

*Wilcoxon's paired test comparing each follow-up value against baseline, with P-values uncorrected for multiple comparison.

Table 3. Dimensional mesial, facial, and distal gingival level changes between different follow-ups and baseline

Follow-up	n	Gingival width						Gingival thickness					
		Mesial		Facial		Distal		Mesial		Facial		Distal	
		r_s^*	P-value	r_s	P-value	r_s	P-value	r_s	P-value	r_s	P-value	r_s	P-value
Provisional	14	0.34	0.234	0.09	0.773	-0.06	0.831	-0.36	0.213	-0.05	0.875	-0.05	0.878
1 month	10	0.21	0.564	0.08	0.834	-0.15	0.688	-0.43	0.211	0.20	0.577	0.26	0.475
12 weeks	10	0.41	0.245	0.22	0.534	-0.15	0.678	-0.41	0.241	0.24	0.513	0.02	0.947
16 weeks	5	0.21	0.734	0.21	0.734	-0.16	0.800	0.00	≈1	0.00	≈1	0.20	0.747
6 months	12	0.30	0.345	-0.46	0.129	-0.24	0.460	-0.27	0.388	-0.26	0.414	0.05	0.888
12 months	12	0.23	0.454	-0.53	0.064	-0.35	0.236	-0.09	0.774	0.18	0.564	0.14	0.653

*Spearman's rank correlation with P-value uncorrected for multiple testing.

wall (Schropp et al. 2003; Cardaropoli et al. 2007; Vignoletti et al. 2009), in many patients barely 0.5 mm of total thickness in its coronal section.

A number of clinical protocols have been suggested to control or minimize the effects of this healing process. A flapless approach (Blanco et al. 2008; Fickl et al. 2008a), grafting of the alveolar space between the implant and the vestibular wall with different biomaterials (Iasella et al. 2003; Chen et al. 2007; Juodzbaly & Wang 2007; Araújo et al. 2009) or the use of immediate implant-supported provisional restoration (Chaushu et al. 2001; Groisman et al. 2003; Kan et al. 2003; Atieh et al. 2009). However, most of these studies focus on implant survival and hard tissue changes, conceding little attention to the soft tissue alterations and final aesthetic outcome.

In the present study, apical changes of the vestibular mucosal margin were minimal at 12 months ($0.45 \text{ mm} \pm 0.25$), as were those of the mesial papilla (0.38 ± 0.60), and slightly larger for the distal papilla (0.80 ± 0.96) with a trimodal approach. Besides, no correlation could be established between patient's gingival biotype or width of the keratinized mucosa and the aforementioned soft tissue alterations for this group of patients.

The utilized measuring system is very accurate and reliable. Previous studies (Chang et al. 1999; Kan et al. 2003; Cornelini et al. 2005) use a reference line linking the marginal tissue level of adjacent teeth, disregarding the possible change in these levels, particularly when a flap is raised. For this reason, later studies (De Rouck et al. 2008, 2009) preferred to use a rigid tooth-supported stent, as we did. This provides a fixed reference point from day 0 (pre-extraction). In this study a digital precision caliper was utilized obtaining precise and reproducible measurements of tenths of a millimeter (for clarity and clinical applicability, some of the figures have been rounded-up to the nearest

tenth). This is a much better means of measurement as compared to previous studies, where a periodontal probe was used. Another interesting feature is the intra-operative measurement of the total periodontal thickness with a precision caliper introduced in the extraction socket. These results are concurrent with those presented using a similar device, a modified caliper (Wax Caliper; Pearson Dental Supply Co., Sylmar, CA, USA) (Kan et al. 2010), and also with those that interpreted conventional radiographic images (Alpiste-Illueca 1994) or cone beam digital images combined with real human specimens measurements (Fu et al. 2010) to determine the periodontal or peri-implant tissue thickness.

The trend in the soft tissue changes over time is shown in Tables 1, 2 and 3. It can be observed that the recession increases slightly over the first 3–4 months, to then level or even recover to initial values, except for the distal papilla. This recovery may be related to the insertion of the final ceramic restoration at 4 months, and is only concurrent with de Rouck's 2008 and 2009 articles while in others (Kan et al. 2003) the recession progressively increases to the 12th month.

The changes at 1 year, however, are very close to those published by the only article using the trimodal approach (Kan et al. 2003), being a little better for the mesial papilla (0.38 mm vs., 0.53 mm) and zenith (0.45 mm vs., 0.55 mm) and slightly worse for the distal papilla (0.80 mm vs., 0.39 mm). Seemingly, our results are close to those presented by authors using different treatment protocols, like ridge preservation (De Rouck et al. 2008, 2009), but better than Cornelini et al. 2005; (0.75 mm facial changes) or Palattella et al. 2008; (up to 0.8 mm buccal soft tissue recession). Other studies published on the topography of the soft tissues after implant placement in healed bone, show similar levels of facial recession after a year of function, close to 0.6 mm (Grunder 2000; Cardaropoli

et al. 2006). Apical movements up to 1 mm . have been described after 3 years, on a conventional protocol (Chang et al. 1999). These results should alert the clinician of a continuous remodeling of the peri-implant tissues, which needs to be monitored long term. Prospective studies monitoring longer follow-up periods in larger patient populations of patients that received implants under this protocol would be desirable, hopefully including Cone Beam Computed Tomography imaging to verify the actual buccal peri-implant bone wall.

The dispersion in the data between the studies may be explained by the difference in follow-up time (some like ours and Kan et al. 2003; measures made from the day of the extraction, others after implant placement and provisional restoration delivery (De Rouck et al. 2009), while some place the provisional crown at 24 h (Cornelini et al. 2005) or at 48 h. (Palattella et al. 2008). Another reason could be the different means to record the measurements. However, data are overall coincident and differences clinically irrelevant.

Little research is available regarding the influence of tissue biotype or width of the attached gingiva on soft tissue changes at the implant-supported restoration when a bimodal or trimodal approach is implemented. In a recent study (Kan et al. 2011) it is suggested that thin biotypes could present a higher aesthetic risk (namely apical recession), noting that the effect of gingival biotype on gingival recession seemed to be limited to the facial aspect only. It has to be mentioned that in this study periodontal patients are not excluded so it could be expected a larger apical migration of the soft tissue after tooth extraction and remodeling around the immediate implant.

Moreover, many of the aforementioned studies exclude thin biotypes from their sample, including only "favorable" patients, likely based on Araújo's studies. To make things harder, no well defined and objective

method to actually sort and classify the various human gingival biotypes is available. Our group is currently committed to this task and hopefully will have some interesting data in the near future. The results of this study suggest that good aesthetic outcomes can be obtained with this treatment protocol, regardless of the patient gingival biotype. As for the implant type (in our sample all implants were Straumann® though Regular Neck TL, Narrow neck and Bone Level implants were used), seems not to influence the outcome, but this was out of the scope of the study and the sample size is not large enough to include this variable. The only reason to use different implant types was the clinical indication for each particular site at the time of surgical planning.

Our data show that, within the limitations of the study, and at 12 months after extraction, soft tissue changes were minimal, in spite of the absence of any hard or soft tissue grafts and the inclusion of thin biotype patients. As these results are unexpectedly favorable, a working hypothesis regarding the importance of the protocol implemented is proposed. In the presented scenario, the provisional restoration, immediately placed, could produce an inhibition by contact effect (Restorative Tissue Inhibitor or RTI). Recent studies (Vignoletti et al. 2009) have shown that "Soft tissue healing to implants placed in fresh extraction sockets may result in a longer epithelial interface than implants placed in a healed ridge". The provisional restoration thus, may act as a contact inhibitor of epithelial cells growth, likely due to blood

clot stability and, as it has also been suggested by Wikesjö (Wikesjö et al. 1999), although other factors may also be involved. Obviously, this is only a hypothesis that needs scientific proof, including histological data.

As for the long-term aesthetic and biological outcome when this trimodal approach is implemented to restore implants in the aesthetic zone, no studies are available. However, our group, as many others do, expects no major changes over time and we are keeping track of the patient pool to record and publish measurements over the years. Although the buccal bone wall thickness was not specifically measured in our study, already mentioned studies have shown it to be extremely thin (under 0.5 mm for most subjects). This may indicate, in the light of our data, that the actual role of the thickness of the buccal alveolar wall as a predictor for aesthetic risk may not be as relevant as previously believed. The fact that the implant position in this protocol is about 2 mm palatal to the buccal bone wall, may allow for a thicker final bone wall buccal to the implant, that will provide the means for long-term hard and soft tissue stability. Studies have shown, in fact, that peri-implant tissues, in general, are much thicker than periodontal tissues (Chang et al. 1999; Tarnow & Chu 2011). This could mean that, by placing the implant palatal to the original tooth root position, we may actually be shifting the patient's biotype from thin to thick, for that particular site. Although an increased risk of complications in post-extraction immediate

implant placement protocols could be expected (Rodrigo et al. 2011), a careful patient selection (integrity of the buccal alveolar wall, ideal preoperative hard and soft tissue levels), and the correct implementation of the trimodal approach seems to produce a very acceptable aesthetic outcome.

Conclusions

Within the limitations of this study, the aesthetic outcome and minimal event of complications seem to validate the trimodal approach protocol as a reliable and simple mean to restore immediate implants in the aesthetic zone. Long-term follow-up of patients treated with this protocol is not available at this point.

No correlation between the patient's gingival biotype and the soft tissue alterations could be established. Additional studies are needed to verify long-term aesthetic results and implant health related variables with this approach and better define and quantify biotypes.

Acknowledgements: The authors thank Prof. Dr. Manuel Bravo, Department of Preventive and Community Dentistry School of Dentistry, University of Granada, Spain, for statistical analysis and advice. Mrs. Susana Yanini CDT, Mr. Javier Pérez López CDT and Mr. August Bruguera CDT, for their excellent laboratory work and their support.

References

- Alpiste-Illueca, F. (1994) Dimensions of the dento-gingival unit in maxillary anterior teeth: a new exploration technique (parallel profile radiograph). *International Journal Periodontics Restorative Dentistry* **24**: 386–396.
- Araújo, M.G., Linder, E. & Lindhe, J. (2009) Effect of a xenograft on early bone formation in extraction sockets: an experimental study in dog. *Clinical Oral Implant Research* **20**: 1–6.
- Araújo, M.G., Sukekava, F., Wennström, J.L. & Lindhe, J. (2005) Ridge alterations following implant placement in fresh extraction sockets: an experimental study in the dog. *Journal Clinical Periodontology* **32**: 645–652.
- Araújo, M.G., Sukekava, F., Wennström, J.L. & Lindhe, J. (2006a) Tissue modelling following implant placement in fresh extraction sockets. *Clinical Oral Implant Research* **17**: 615–624.
- Araújo, M.G., Wennström, J.L. & Lindhe, J. (2006b) Modeling of the buccal and lingual bone walls of fresh extraction sites following implant installation. *Clinical Oral Implant Research* **17**: 606–614.
- Atieh, M.A., Payne, A.G.T., Duncan, W.J. & Cullinan, M.P. (2009) Immediate restoration/loading of immediate placed single implants: is it an effective bimodal approach? *Clinical Oral Implant Research* **20**: 645–659.
- Bianchi, A.E. & Sanfilippo, F. (2004) Single-tooth replacement by immediate implant and connective tissue graft: a 1-9 year clinical evaluation. *Clinical Oral Implant Research* **15**: 269–277.
- Blanco, J., Nuñez, V., Aracil, L., Muñoz, F. & Ramos, I. (2008) Ridge alterations following immediate implant placement in the dog: flap versus flapless surgery. *Journal of Clinical Periodontology* **35**: 640–648.
- Botticelli, D., Berglundh, T. & Lindhe, J. (2003b) The jumping distance revisited: an experimental study in the dog. *Clinical Oral Implant Research* **14**: 35–42.
- Cardaropoli, D., Debernardi, C. & Cardaropoli, G. (2007) Immediate placement of implant into impacted maxillary canine extraction socket. *International Journal of Periodontics and Restorative Dentistry* **27**: 71–77.
- Cardaropoli, G., Lekholm, U. & Wennstrom, J.L. (2006) Tissue alterations at implant-supported single-tooth replacements: a 1-year prospective clinical study. *Clinical Oral Implants Research* **17**: 165–171.
- Chang, M., Wennström, J. L., Ödman, P. & Andersson, B. (1999) Implant supported single-tooth replacements compared to contralateral natural teeth. Crown and soft tissue dimensions. *Clinical Oral Implants Research* **10**: 185–194.
- Chausu, G., Chausu, S., Tzohar, A. & Dayan, D. (2001) Immediate loading of single tooth implants: immediate versus non-immediate implantation. A clinical report. *International Journal of Oral & Maxillofacial Implants* **16**: 267–272.
- Chen, S.T., Darby, I.B. & Reynolds, E.C. (2007) A prospective clinical study of non-submerged immediate implants: clinical outcomes and aesthetic results. *Clinical Oral Implant Research* **18**: 552–562.

- Chen, S.T., Wilson, T.G. Jr & Hämmerle, C.H. (2004) Immediate or early placement of implants following tooth extraction: review of biologic basis, clinical procedures and outcomes. *The International Journal of Oral & Maxillofacial Implants* **19**(Suppl): 12–25.
- Cornelini, R., Cangini, F., Covani, U. & Wilson, T. G. Jr (2005) Immediate restoration of implants placed into fresh extraction sockets for single tooth replacement: a prospective clinical study. *International Journal of Periodontics and Restorative Dentistry* **25**: 439–447.
- Evans, C.D. & Chen, S.T. (2008) Aesthetic outcomes of immediate implant placements. *Clinical Oral Implants Research* **19**: 73–80.
- Fickl, S., Zuhr, O., Wachtel, H., Boltz, W. & Hurzeler, M. (2008a) Tissue alterations after tooth extraction with and without surgical trauma: a volumetric study in the beagle dog. *Journal of Clinical Periodontology* **35**: 356–363.
- Fu, J.H., Yeh, C.Y., Chan, H.L., Tatarakis, N., Leong, D. & Wang, H.L. (2010) Tissue biotype and its relation to the underlying bone morphology. *Journal Periodontology* **81**: 569–574.
- Gottfredsen, K. (2004) A 5-year prospective study of single-tooth replacements supported by the Astra Tech implant: a pilot study. *Clinical Implant Dentistry & Related Research* **6**: 1–8.
- Groisman, M., Frossard, W.M., Ferreira, H.M., de Menezes Filho, L.M. & Touati, B. (2003) Single tooth implants in the maxillary incisor region with immediate provisionalization: 2 year prospective study. *Practical Procedures and Aesthetic Dentistry* **15**: 115–122.
- Grunder, U. (2000) Stability of the mucosal topography around single-tooth implants and adjacent teeth: 1-year results. *International Journal of Periodontics and Restorative Dentistry* **20**: 11–17.
- Iasella, J.M., Greenwell, H., Miller, R.L., Hill, M., Drisko, C., Bohra, A.A. & Scheetz, J.P. (2003) Ridge preservation with freeze-dried bone allograft and collagen membrane compared to extraction alone for implant site development: a clinical and histological study in humans. *Journal of Periodontology* **74**: 990–999.
- Jemt, T. (1997) Regeneration of gingival papillae after single-implant treatment. *International Journal Periodontics and Restorative Dentistry* **17**: 327–333.
- Juodzbalys, G. & Wang, H.L. (2007) Soft and hard tissue assessment of immediate implant placement: a case series. *Clinical Oral Implant Research* **18**: 237–243.
- Kan, J.Y., Morimoto, T., Rungcharassaeng, K., Roe, P. & Smith, D.H. (2010) Gingival biotype assessment in the esthetic zone: visual versus direct measurement. *International Journal of Periodontics Restorative Dentistry* **30**: 237–243.
- Kan, J.Y., Rungcharassaeng, K. & Lozada, J. (2003) Immediate placement and provisionalization of maxillary anterior single implants: 1-year prospective study. *The International Journal of Oral & Maxillofacial Implants* **18**: 31–39.
- Kan, J.Y., Rungcharassaeng, K., Lozada, J.L. & Zimmerman, G. (2011) Facial gingival tissue stability following immediate placement and provisionalization of maxillary anterior single implants: A 2- to 8-year follow-up. *International Journal of Oral and Maxillofacial Implants* **26**: 179–187.
- Lang, N.P., Tonneti, M.S., Suvan, J.E., Pierre Bernard, J., Boticelli, D., Fourmousis, I., Hallund, M., Jung, R., Laurell, L., Salvi, G.E., Shafer, D. & Weber, H.P. (2007) Immediate implant placement with transmucosal healing in areas of aesthetic priority. A multicentre randomized-controlled clinical trial. I. Surgical outcomes. *Clinical Oral Implant Research* **19**: 188–196.
- Norton, M.R. (2004) A short-term clinical evaluation of immediately restored maxillary TiOblast single-tooth implants. *The International Journal of Oral & Maxillofacial Implants* **19**: 274–281.
- Palattella, P., Torsello, F & Cordaro, L. (2008) Two-year prospective clinical comparison of immediate replacement vs. immediate restoration of single tooth in the esthetic zone. *Clinical Oral Implant Research* **19**: 1148–1153.
- Paolantonio, M., Dolci, M., Scarnano, A., d'Archivio, D., diPlacido, G., Tummi, V. & Piatelli, A. (2001) Immediate implantation in fresh extraction sockets. A controlled clinical and histological study in man. *Journal of Periodontology* **72**: 1560–1571.
- Quirynen, M., VanAssche, N., Boticelli, D. & Berglundh, T. (2007) How does the timing of implant placement to extraction affect outcome? *The International Journal of Oral & Maxillofacial Implants* **22**(Suppl): 203–223.
- Rodrigo, D, Martin, C & Sanz, M. (2011) Biological complications and peri-implant clinical and radiographic changes at immediately placed dental implants. A prospective 5-year cohort study. *Clinical Oral Implant Research* **18**: 1–8.
- DeRouck, T., Collys, K. & Cosyn, J. (2008) Immediate single-tooth implants in the anterior maxilla: a 1-year case cohort study on hard and soft tissue response. *Journal Clinical Periodontology* **35**: 649–657.
- DeRouck, T, Collys, K, Wyn, I & Cosyn, J. (2009) Instant provisionalization of immediate single-tooth implants is essential to optimize esthetic treatment outcome. *Clinical Oral Implants Research* **20**: 566–570.
- Schropp, L., Kostopoulos, L. & Wenzel, A. (2003) Bone healing following immediate versus delayed placement of titanium implants into extraction sockets: a prospective clinical study. *The International Journal of Oral & Maxillofacial Implants* **18**: 189–199.
- Schwartz-Arad, D. & Chaushu, G. (1998) Immediate implant placement: a procedure without incisions. *Journal of Periodontology* **69**: 743–750.
- Tarnow, DP & Chu, SJ. (2011) Human histological verification of osseointegration of an immediate implant placed into a fresh extraction socket with excessive gap distance without primary flap closure, graft, or membrane: a case report. *International Journal of Periodontics & Restorative Dentistry* **31**: 515–21.
- Vignoletti, F., de Santis, M., Berglundh, T., Abrahamsson, I. & Sanz, M. (2009) Early healing of implants placed into fresh extraction sockets: an experimental study in the beagle dog. III Soft tissue findings. *Journal Clinical Periodontology* **36**: 1059–1066.
- Wikesjö, U.M., Guglielmoni, P., Promsudhi, A., Cho, K.S., Trombelli, L., Selvig, K.A., Jin, L. & Wozney, J.M. (1999) Periodontal repair in dogs: effect of rhBMP-2 concentration on regeneration of alveolar bone and periodontal attachment. *Journal of Clinical Periodontology* **26**: 392–400.